
RESENTING CLINICAL SIGNS

History: Had pericardiocentesis performed last week. No obvious mass seen then. Pericardial effusion has reaccumulated. Echo performed following pericardiocentesis.

DATE

9/7/21

ECHOCARDIOGRAPHIC FINDINGS

2D, M-mode, and Doppler study.

PERFORMED BY:

Dr. Brian Barnes

INTERPRETED BY

 Keith Blass, DVM,
 MS, DACVIM
 (Cardiology)

A mild to moderate volume pericardial effusion is present (pre-pericardiocentesis). Left atrial size is normal. The mitral valve is normal. Left ventricular dimensions are normal. Left ventricular systolic function is mildly hyperdynamic. The aorta and aortic valve are normal. Right atrial and right ventricular dimensions are normal. There is diastolic collapse of the right atrial free wall (pre-pericardiocentesis). The tricuspid valve appears normal, though trace tricuspid regurgitation is present. The pulmonary artery and pulmonic valve are normal. No heartworms are visualized. No shunting lesions are visualized. There is an ~3.20 cm x 2.50 cm mass originating from the right atrium/right atrioventricular (AV) groove.

ECG during echo: Sinus rhythm with a single VPC

PATIENT

Roxy Thiesen

LA – 35.4 mm (prev. 36.4 mm)
 LVIDd – 36.4 mm (prev. 32.9 mm)
 LVIDs – 20.1 mm (prev. 20.0 mm)
 FS – 44.8% (prev. 39%)
 RA – 31.6 mm
 LVOT – 1.50 m/s (prev. 1.40 m/s)
 RVOT – 1.05 m/s (prev. 1.10 m/s)

SPECIES

Canine

ASSESSMENT/RECOMMENDATIONS
BREED

This examination confirms the presence of a mass associated with Roxy's right atrium/AV groove, and it's very likely that bleeding from the mass has resulted in her pericardial effusion formations.

Boxer

Masses in this location in dogs are most commonly hemangiosarcomas, though a definitive diagnosis can only be obtained via biopsy. If hemangiosarcoma is present, this tumor type is typically an aggressive one, with metastasis to the lungs and/or abdominal organs being very common.

SEX
FS

Only trace residual pericardial effusion is seen in the post-pericardiocentesis images, therefore, repeat pericardiocentesis does not appear to be necessary at this time. Consideration can be given to a palliative pericardiectomy, as this procedure should prevent additional episodes of cardiac tamponade.

AGE
8 y

Thoracic radiographs and an abdominal ultrasound are recommended to evaluate for metastatic disease.

WEIGHT

33.3 kg

Referral to an oncologist may be warranted to determine whether chemotherapy and/or radiation therapy could potentially be beneficial treatment options.

HOSPITAL NAME

Westview VH

A recheck echocardiogram is recommended in 3 months, sooner if clinical signs compatible with tamponade recur.

REFERRING VET

Dr. Barnes



DATE

9/7/21

PERFORMED BY:

Dr. Brian Barnes

INTERPRETED BY

Keith Blass, DVM,
MS, DACVIM
(Cardiology)

PATIENT

Roxy Thiesen

SPECIES

Canine

BREED

Boxer

SEX

FS

AGE

8 y

WEIGHT

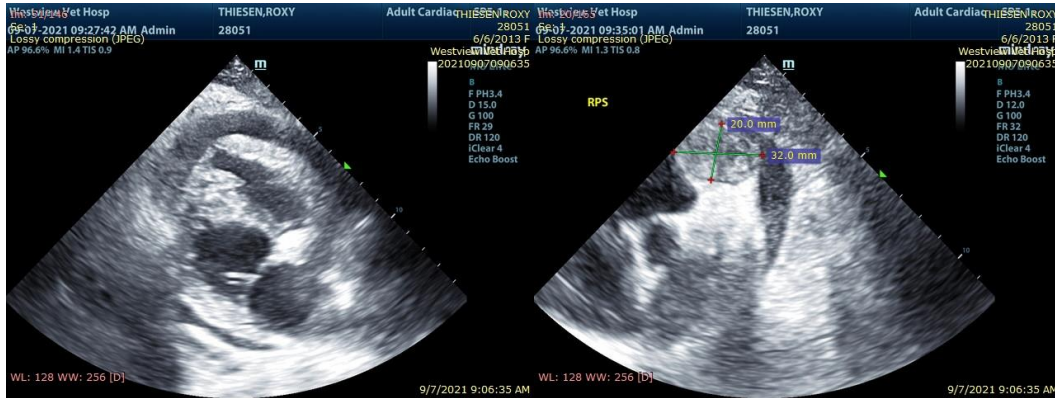
33.3 kg

HOSPITAL NAME

Westview VH

REFERRING VET

Dr. Barnes



The information and recommendations provided are based on the images presented by the referring veterinarian. No evaluation can be communicated regarding pathology that was not visible in the image/video clips provided.

Thank you for this referral. If the clinical or image interpretation does not parallel your findings or if I can be of any further assistance please contact me.

Keith Blass, DVM, MS, DACVIM (Cardiology)
KeithBlass@gmail.com
631-804-5754